



EVALUATION OF EFFICACY OF ULTRASOUND GUIDED, ALCOHOL BASED, NEUROLYTIC INTERCOSTAL BLOCKS IN POST HERPETIC NEURALGIA- AN OBSERVATIONAL STUDY.

¹Dr. G Jayaraman MD. and ²*Dr. S. Parthasarathy MD. DNB. PhD.

¹Assistant Professor, Department of Radiodiagnosis, Mahatma Gandhi Medical college and Research Institute, Puducherry – South India.

²Professor, Department of Anesthesiology, Mahatma Gandhi Medical College and Research Institute, Puducherry – South India.

***Corresponding Author: Dr. S. Parthasarathy**

Professor, Department of Anesthesiology, Mahatma Gandhi Medical College and Research Institute, Puducherry – South India.

Article Received on 26/05/2018

Article Revised on 14/06/2018

Article Accepted on 05/07/2018

ABSTRACT

Post-herpetic neuralgia (PHN) is one of the most common and important complication of severe Varizella Zoster infection particularly occurring in 20% of the elderly patients for one year. PHN is defined as neuropathic pain which is persisting for 90-120 days after the acute phase of herpes zoster. Various treatment modalities including interventional blocks have been described. In our initial study of six patients of established PHN, we administered ultrasound guided neurolytic intercostal nerve block to get excellent relief in all our patients. This was done after establishing the dermatome with a test block with only local anesthetics. This analgesia persisted for three more months. There were no complications. We feel that the use of ultrasound has revolutionised such neurolytic blocks to be administered without having in mind the possible complications. To conclude, ultrasound guided, alcohol based, neurolytic intercostal blocks is efficacious in the management of post herpetic neuralgia without much side effects.

KEYWORDS: chronic pain, post herpetic neuralgia, nerve block, intercostal, alcohol.

INTRODUCTION

Post herpetic neuralgia (PHN) is one of the most resistant chronic pain problems, usually affecting elderly patients. The pain of PHN usually follows the typical dermatomal distribution of the erythematous rash caused by herpes zoster. Commonly unilateral thoracic dermatomes and the trigeminal nerve, especially the ophthalmic branch, are frequently affected.^[1] Despite adequate treatment 20 % suffer from the disease. Anticonvulsants, sympathetic, intercostal, paravertebral and epidural blocks have been used with variable success.^[2] Neurolysis with alcohol/phenol can extend analgesia for a few months during which the intensity of the disease may decrease. Earlier, neurolysis of intercostal nerve was fraught with apprehensions of pleural damage. The introduction of ultrasound to identify the intercostal space and the possibility of completely avoiding the pleura has thrown light on the resurgence of the technique.^[3] Hence in this initial pilot observational study of six patients with established PHN we tried to establish the efficacy of alcohol based intercostal nerve neurolysis.

METHODS

Six patients of established post herpetic neuralgia were selected after prior consent. All patients had a history of herpes zoster three to four months ago and undergone various modalities of treatment which included antivirals, anticonvulsants and antidepressants. Patients with persistent burning pain in the dermatomal region strictly involving one side which is refractory and debilitating were taken up for the study. They were explained about the visual analogue scale of pain (0- 10). The zoster of the intercostal nerve was only selected. All patients were administered ultrasound guided intercostal nerve block with local anaesthetic (i.e. 8 ml of 0.25 % bupivacaine) and the identification of the space was done with the same. The following day, all patients were given 8 ml of the mixture of 4 ml of 0.5 % bupivacaine with 4 ml of 100 % alcohol which means the total mixture contains 50 % alcohol only. The injection was administered after exact identification of the space by the use of ultrasound (Sonosite X Porte). The spread was well visualized in the ultrasound with appropriate identification of the pleura (Fig1). The immediate VAS scores were noted along with scores at one, and three months interval. All patients were asked to continue the

last administered drug which was carbamazepine 600 mg/ day in divided doses. They were instructed to report any complication or the increase in pain with a VAS score of more than 4. The terms VAS 0 was defined as score before the block while VAS1 was immediate relief: VAS 2 after one month and VAS 3 after three months. Any drop outs were noted.

Table 1: showing demographic data of the patients.

Patient number	Age	sex	Weight (Kg)	Dermatome
1	65	M	62	T4
2	73	M	63	T6
3	72	M	65	T4
4	70	F	61	T6
5	69	M	70	T4
6	65	F	64	T6

There was a significant reduction in the pain scores from day 1 up to 3 months. The reduction was very significant in that the VAS scores came down to near 1 or 2 in all the cases. The reduction in pain scores persisted for three months. See table 2.

RESULTS

All the six patients completed the study. There were no drop outs. The demographic data of the six patients were tabled below.

Table 2: showing VAS pain scores at different times.

Patient	VAS 0	VAS1	VAS2	VAS 3
1	7	1	1	1
2	8	0	2	2
3	8	1	1	2
4	9	0	2	2
5	8	0	1	2
6	7	1	1	1

There were no major side effects. There was cough in one patient who was a known occasional wheezer treated with bronchodilators. The repeat ultrasound done for him was normal in the immediate post procedure scenario.

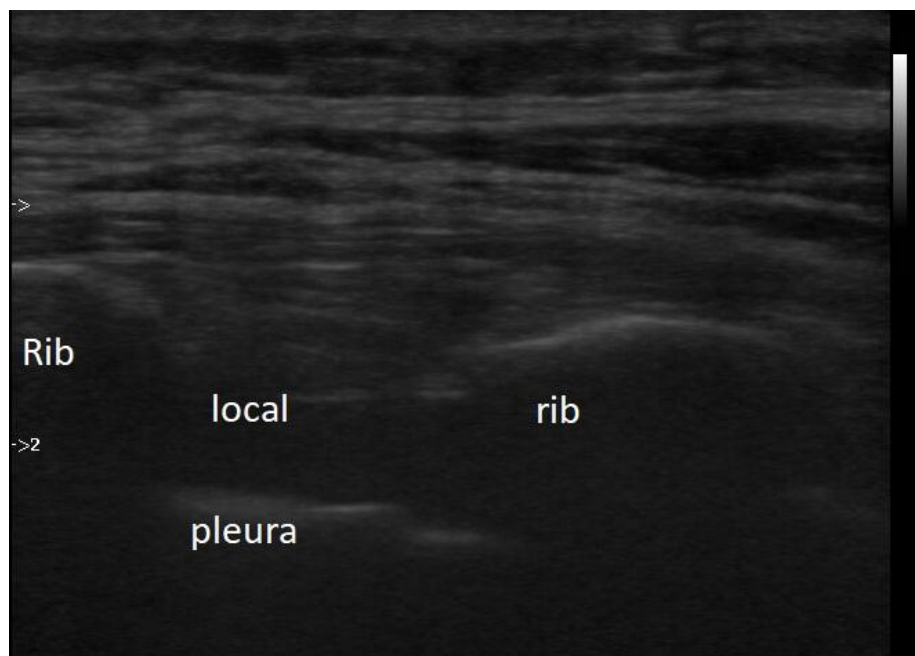


Fig 1: showing the spread of local anesthetics in the intercostal nerve area.

DISCUSSION

Post herpetic neuralgia (PHN) is a neuropathic pain syndrome which occurs following an acute herpes zoster infection. The main clinical problem is intractable pain which interferes with activity of daily life with reduction in the quality of life in elderly patients. Intractable pain

was found to be occurring in 20 – 40 % according to different studies. All patients were Grade 1 according to Rowbotham^[4] criteria before the administration of the block.

1. The irritable nociceptive group, with mechanical allodynia and normal or hyperalgesic thermal sensation
2. The central reorganization group with mechanical allodynia and thermal sensory deficits
3. The deafferentation group with ongoing pain, without allodynia, and profound sensory loss.

Intercostal nerve block has been used with variable results in patients with PHN. A thorough search of the internet revealed very few successful neurolytic blocks for treatment of PHN. We have successfully used neurolytic intercostal nerve block in all our patients. The significant reduction of VAS scores which persisted for three months was the highlight of our work. In malignant chest pain, there were studies which proved the efficacy of neurolytic blocks which also was effective in four out of six patients.^[5] We did get 100% results. In our series, there were no post procedural complications like any obvious motor deficit which could have been possible with epidural spread. This was possibly due to the use of ultrasound and precise deposition of the drug mixture. Chau *et al*^[6] have described that appropriate nerve blocks with continuous drugs gives satisfactory analgesia in a majority of patients. But in our study, it was found in all the cases and the analgesia was complete. The most common site of PHN is thoracic area in many studies.^[7] In our study also, we handpicked thoracic dermatomal lesions only to study the efficacy of our intervention. There was one report of paraplegia with neurolytic intercostal block in a patient with lung cancer which later proved to be due to spinal cord involvement.^[8] We did not encounter any major complications. Paravertebral block has been used in patients with PHN with variable success but it is technically more demanding to administer than intercostal blocks with a danger of epidural spread which can cause dangerous consequences with the use of alcohol. In our cases many drug combinations were tried with local patches but with inadequate pain relief. But after three months, they were given only carbamazepine in good doses to monitor the effect of our block. This obviously removes any bias on the efficacy of the block. The biggest limitation of our study is the sample size. We have not compared with any other treatment modality with respect to either complications or efficacy.

CONCLUSION

To conclude, in cases with intractable postherpetic neuralgia, ultrasound guided neurolytic intercostal nerve block is very useful in alleviating immediate pain along with significant relief of persistent pain. There were no major complications.

REFERENCES

1. Gauthier A, Breuer J, Carrington D, Martin M, Rémy V. Epidemiology and cost of herpes zoster and post-herpetic neuralgia in the United Kingdom. *Epidemiol Infect*, 2009; 137: 38-47.

2. Dworkin RH, Schmdar KE. Treatment and prevention of postherpetic neuralgia. *Clin Infect Dis*, 2003; 36: 877-2.
3. Stone, Michael B. *et al.* Ultrasound-guided intercostal nerve block for traumatic pneumothorax requiring tube thoracostomy. *The American Journal of Emergency Medicine*, 29(6): 697.e1-697.e2.
4. Rowbotham MC, Peterson KL, Fields HL. Is post herpetic neuralgia more than one disorder? *Pain Forum*, 1998; 7: 231-7.
5. Matchett G. Intercostal Nerve Block and Neurolysis for Intractable Cancer Pain. *J Pain Palliat Care Pharmacother*, 2016 J; 30(2): 114-7.
6. Chau SW, Soo LY, Lu DV, Chen T, Cheng K, Chu KS. Clinical experience of pain. treatment for postherpetic neuralgia in elderly patients. *Acta Anaesthesiol Taiwan*, 2007; 45(2): 95-101.
7. Francis Sahngun Nahm, Sang Hun Kim, Hong Soon Kim *et al.* Survey on the Treatment of Postherpetic Neuralgia in Korea; Multicenter Study of 1,414 Patients. *Korean J Pain*, 2013; 26(1): 21-26.
8. Byoung Ho Kim, Min Young No, Sang Ju Han, Cheol Hwan Park, and Jae Hun Kim. Paraplegia Following Intercostal Nerve Neurolysis with Alcohol and Thoracic Epidural Injection in Lung Cancer Patient. *Korean J Pain*, 2015; 28(2): 148-152.