



## SPLENOMEGALY

**Dr. Jaspal Singh<sup>\*1</sup>, Dr. Shrikant Patel<sup>2</sup>, Dr. Sucheta Ray<sup>3</sup> and Dr. Rohit Jain<sup>4</sup>**

<sup>1</sup>M.S. Scholar, <sup>2</sup>Reader, <sup>3</sup>Reader Dept. of Shalya Tantra, <sup>4</sup>Lecturer Dept. of Shalakyta Tantra  
Rani Dullaiya Smriti Ayurved P.G. Mahavidhyalaya Evam Chikitsalaya Bhopal (M.P).

**\*Corresponding Author: Dr. Jaspal Singh**

M.S. Scholar, Rani Dullaiya Smriti Ayurved P.G. Mahavidhyalaya Evam Chikitsalaya Bhopal (M.P).

Article Received on 24/12/2018

Article Revised on 14/01/2019

Article Accepted on 04/02/2019

### ABSTRACT

Splenomegaly is defined as enlargement of the spleen measured by size or weight. The spleen plays a significant role in hematopoiesis and immunosurveillance. The major functions of the spleen include clearance of abnormal erythrocytes, removal of microorganisms and antigens as well as the synthesis of immunoglobulin G (IgG). The spleen also synthesizes the immune system peptides properdin and tuftsin. Also, approximately one-third of circulating platelets are stored in the spleen. The normal position of the spleen is within the peritoneal cavity in the left upper quadrant adjacent to ribs 9 through 12. The normal sized spleen is usually not palpable in adults. However, it may be palpable due to variations in body habitus and chest wall anatomy. Splenomegaly may be diagnosed clinically or radiographically using ultrasound, CT imaging, or MRI. Splenomegaly may be a transient condition due to acute illness or may be due to serious underlying acute or chronic pathology.

**KEYWORDS:** Spleen, splenomegaly, Embryonic origin.

### Normal Spleen

It is a wedge shaped organ lying mainly in left hypochondrium, along the long axis of 10<sup>th</sup> rib and to the left of the stomach. It is the largest lymphoid organ and highly vascular. The spleen varies in the size and shape between people.

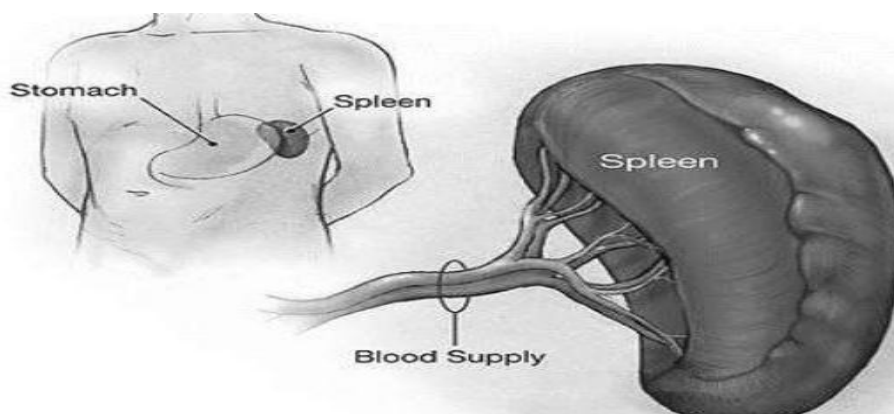
**Normal size** – 12cm length, 7cm width and 3-4cm thick.

**Weight** - < 250gm.

**Located** – 9<sup>th</sup> 10<sup>th</sup> 11<sup>th</sup> ribs mid-axillary.

Spleen should be twice in size to be **PALPABLE**

Palpable spleen are not always **ABNORMAL**



### Embryonic Origin of Spleen

- \* The spleen is a vertebrate organ that has a hematopoietic and immunologic function.
- \* The embryonic origin of spleen are obscure, with most studies describing the earliest rudiment of the spleen as a condensation of mesodermal mesenchyme on the left side of dorsal mesogastrium.

### Function of Spleen

#### Cellular Function

- Formation of blood cell :- Spleen plays an important role in the hemopoietic function in embryo. It is an important site of RBCs production till five months of gestation.
- Destruction of blood cells :- Older RBCs, lymphocytes and thrombocytes are destroyed in the

spleen, when the RBCs become old (120days) the cell membrane become more fragile, removal of older RBCs is done by a process called “culling”. Destruction of RBCs occurs mostly in the capillaries of spleen because the Splenic capillaries have a thin lumen so the spleen known as “Graveyard of RBCs.”

- +
- Blood reservoir function :- In animals spleen stores large amount of blood. However this function is not significant in human but a large number of RBCs are stored in spleen, the RBCs are released from spleen into circulation during the emergency condition like hypoxia and haemorrhage.

#### Immunologic Function

- ROLE IN DEFENSE OF BODY:- By secreting antibodies like IgM, tuftsin, opsonin, properdin, interferons. Spleen stimulates the phagocytic activity of leucocytes. After splenectomy patients are more

prone for OPSI (overwhelming post splenectomy infection).

#### Surgical Anatomy

Two surface:- Diaphragmatic & Visceral

Two ends :- Anterior & posterior

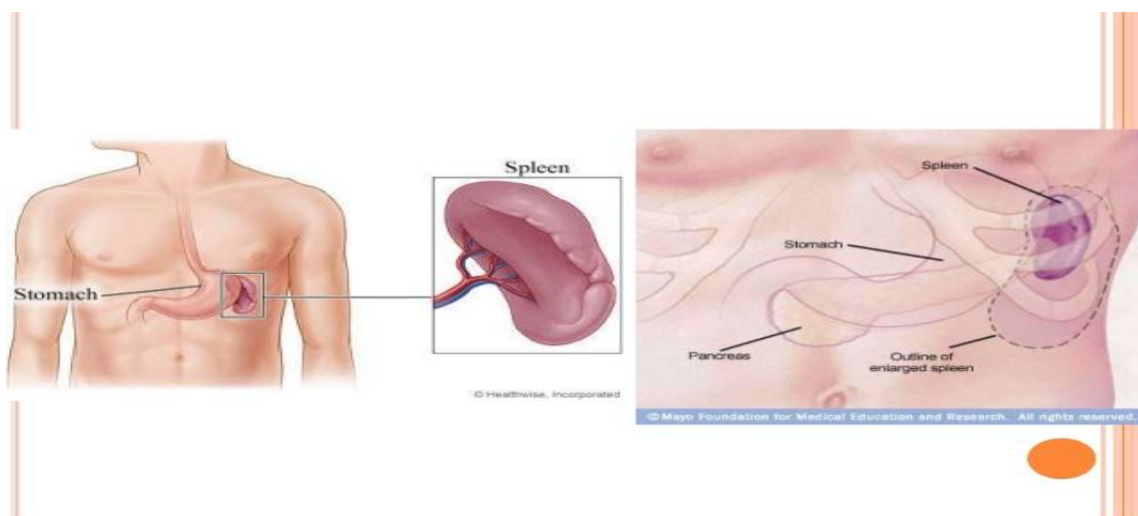
Two border :- Superior & Inferior

It lies in intimate contact with the under surface of diaphragm, when blood collect due to splenic injury, it irritate the diaphragm causing referred pain to the shoulder tip (KEHR'S SIGN).

#### Splenomegaly

##### Definition

Splenomegaly and hypersplenism should not be confused. Each may be found separately. Clinically, if a spleen is palpable (felt via external examination), it means it is enlarged as it has to undergo at least twofold enlargement to become palpable. However, the tip of the spleen may be palpable in a newborn baby up to three months of age.



#### Classification

Splenomegaly can be classify as :-

Mild

Moderate

Massive

Mild splenomegaly - just palpable

1- 3 cm more than normal

Spleen > 400g < 1000g

Moderate splenomegaly – Between costal margin and umbilicus

4- 8 cm more than normal spleen

Spleen >400 g <1000 g

Massive splenomegaly- Beyond umbilicus, crosses midline into pelvis

Spleen >8 cm than normal

Spleen >1000 g

#### Etiology of Splenomegaly

Number of infections and diseases may cause an enlarged spleen. The enlargement of the spleen may be

temporary, depending on treatment. Contributing factors include:-

- Viral infections, such as mononucleosis
- Bacterial infections, such as syphilis or an infection of your heart's inner lining (endocarditis)
- Parasitic infections, such as malaria
- Cirrhosis and other diseases affecting the liver
- Various types of hemolytic anemia — a condition characterized by early destruction of red blood cells
- Blood cancers, such as leukemia and myeloproliferative neoplasms, and lymphomas, such as Hodgkin's disease
- Metabolic disorders, such as Gaucher's disease and Niemann-Pick disease
- Pressure on the veins in the spleen or liver or a blood clot in these veins

#### Symptoms

- No symptoms in some cases

- Pain or fullness in the left upper abdomen that may spread to the left shoulder
- Feeling full without eating or after eating only a small amount from the enlarged spleen pressing on your stomach
- Anemia
- Fatigue
- Frequent infections
- Easy bleeding

#### Differential Diagnosis

- Enlarge left Kidney
- Enlarge left lobe Liver
- Carcinoma Stomach
- Carcinoma Splenic flexure Colon
- Omental Mass
- Malignancy tail of Pancrease

#### Evaluation

- A combination of serum testing and imaging studies may definitively diagnose splenomegaly and the underlying cause. Derangement in the complete blood (cell) counts and morphology including WBC, RBC, and platelets will vary based on underlying disease state. Abnormalities in liver function tests, lipase, rheumatologic panels, and disease-specific infectious testing aid in the diagnosis of causative disease.
- Imaging may be used to diagnose splenomegaly and elucidate its underlying cause. The spleen has a similar attenuation as the liver when measured on CT imaging. In addition to diagnosing splenomegaly (splenic measurement of greater than 10 cm in craniocaudal length), abdominal CT may detect splenic abscess, mass lesions, vascular abnormalities, cysts, inflammatory changes, traumatic injury, intra-abdominal lymphadenopathy, or liver abnormalities.
- Ultrasound is a useful imaging modality in measuring the spleen and spares the patient radiation from CT imaging. Normal spleen size measured via ultrasound is less than 13 cm superior to the inferior axis, 6 cm to 7 cm in medial to lateral axis and 5 cm to 6 cm in anterior to posterior plane.
- MRI, PET scans, liver-spleen colloid scanning, and splenectomy and splenic biopsy may be indicated in certain cases.

#### Treatment

Treatment of splenomegaly is targeted at treating the underlying disease and protecting the patient from complications of splenomegaly itself. Patients with splenomegaly from any cause are at increased risk of splenic rupture, and increased attention must be made to protect the patient from abdominal trauma. Treatment ranges from abdominal injury avoidance in the young healthy patient with splenomegaly due to infectious mononucleosis, to splenectomy of a massively enlarged spleen in a patient with Hairy cell leukemia. Likewise,

the prognosis is largely dependent on underlying disease state.

Chemotherapy is used for hematologic malignancies. Antibiotics are used for infection, with the exception of infection associated with a splenic abscess, this requires surgical intervention. Immunosuppression is used for autoimmune or inflammatory disorders.

In most cases, treatment of the underlying cause of the enlarged spleen can prevent removal of the spleen. In some cases, the spleen will need to be removed surgically (splenectomy). If surgery is needed, a surgeon is likely to remove the spleen using laparoscopy rather than open surgery.

Laparoscopic splenectomy is done using an instrument called a laparoscope. This is a slender tool with a light and camera on the end. The surgeon makes three or four small cuts in the abdomen, and inserts the laparoscope through one of them. This allows the doctor to look into the abdominal area and locate the spleen. Different medical instruments are passed through the other openings. One of them is used to deliver carbon dioxide gas into the abdominal area, which pushes nearby organs out of the way and gives your surgeon more room to work. The surgeon disconnects the spleen from surrounding structures and the body's blood supply, and then removes it through the largest surgical opening. The surgical openings are closed using stitches or sutures.

Open splenectomy requires a larger surgical cut than the laparoscopic method. The surgeon makes an incision across the middle or left side of your abdomen underneath the rib cage. After locating the spleen, the surgeon disconnects it from the pancreas and the body's blood supply, and then removes it. The surgical openings are closed using stitches or sutures.

#### DISCUSSION

Spleen is composed of two primary regions namely, red pulp and white. The red pulp makes up for little more than three-fourth of the spleen. Red pulp is red because it has many small cavities (sinusoids) where the spleen stores blood in case of injury or other situations where the body needs extra blood. This blood reserve has a high count of platelets, an essential component for blood coagulation to help stop bleeding. Red pulp also removes and recycles components of old, damaged and dead red blood cells.

White pulp is associated with the lymphatic function of the spleen. Most of this tissue consists of lymph-related nodules, called Malpighian corpuscles. It also produces and stores white blood cells (lymphocytes).

**CONCLUSION**

Spleen is a vital organ which plays an important role in blood reservoir. Its size differ in people but palpable spleen is not always abnormal.

Main cause of splenomegaly is infection which show main symptom of pain at LUQ. Its first line of treatment is cure infection and in rare cases splenectomy is indicated.

**BIBLIOGRAPHY**

1. GRAY'S Anatomy: Anatomy basis of clinical practice. Editor chief Susan Standring forth edition, 2008.
2. Roshan lall Gupta: Text book of surgery. Second edition, 2003.
3. Zaorsky NG, Williams GR, Barta SK, Esnaola NF, Kropf PL, Hayes SB. Splenic irradiation for splenomegaly: A systematic review. Rev., 2017 Feb.
4. Rabushka LS, Fishman EK. Imaging of the spleen: CT with supplemental MR examination. Radiographics, 1994 Mar.
5. Bailey and love's: 23<sup>rd</sup> edition 2000.
6. S Das: 6<sup>th</sup> edition 2004.
7. Manipal manual of surgery: Second edition, 2005.
8. Trappey B, Wagner M, Newman M, Nixon LJ, Schnobrich D. Point-of-care ultrasonography improves the diagnosis of splenomegaly in hospitalized patients, 2015 Dec.